

# ST-Elevation myocardial infarction, severe cardiogenic shock, and myocarditis secondary to leptospirosis: A rare case report

Coana Sukmagautama<sup>1\*</sup>, Faizal Muhammad<sup>2</sup>, Ken Zuraida Maharestri<sup>1</sup>, Ihsan Hanif<sup>1</sup>, Risalina Myrtha<sup>3</sup>

<sup>1</sup>Internal Medicine Department, Faculty of Medicine, Sebelas Maret University, Surakarta, Indonesia

<sup>2</sup>Neurology Department, Faculty of Medicine, Sebelas Maret University, Surakarta, Indonesia

<sup>3</sup>Cardiology and Vascular Medicine Department, Faculty of Medicine, Sebelas Maret University, Surakarta, Indonesia

## Abstract

**Background:** Leptospirosis is a bacterial infection that can lead to several organ dysfunctions. The unknown pathogenesis and association between leptospirosis and cardiac involvements can lead to a diagnostic challenge and case rarity. This study aims to report a diagnosis challenge through physical and laboratory examination of a patient with ST-elevation myocardial infarction (STEMI) and myocarditis without common leptospiral-associated organ dysfunction features.

**Case:** A 35-year-old male patient came to the emergency department with flu-like symptoms. Twenty-four hours later, the patient showed acute angina, STEMI, and elevated high-sensitivity cardiac troponin followed by cardiogenic shock without significant modifiable and non-modifiable risk factors for heart diseases. The patient received fibrinolytic, supportive therapy and correction of hemodynamic derangement. We found thrombocytopenia on the second day. Surprisingly, the immunoserology showed positive anti-leptospira IgM and negative anti-dengue IgM and IgG. Direct cardiac tissue damage due to systemic vasculitis, disseminated intravascular coagulation, and pro-inflammatory cytokine storm is believed to be pathomechanism in leptospirosis with cardiac involvement. After diagnosis establishment, his final therapies in the hospital were Aspirin, Atorvastatin, Clopidogrel, Spironolactone, Ramipril, Carvedilol, Omeprazole, Doxycycline, and Ceftriaxone. Subsequently, he was discharged from hospital and continued to receive cardiovascular medications, antibiotics, antiplatelet, potassium-sparing diuretics, and omeprazole.

**Conclusion:** This case highlights the importance of thorough clinical-laboratory evaluation in a patient with an atypical leptospiral presentation. Although leptospirosis is not a common cause of heart diseases such as STEMI, cardiogenic shock, and myocarditis, we recommend supportive therapy and correction of hemodynamic derangement for leptospirosis with cardiac involvement, in addition to leptospiral antibiotic drug itself.

**Keywords:** cardiogenic shock; heart disease; leptospirosis; myocardial infarction; myocarditis

## Introduction

Leptospirosis is a zoonosis disease caused by the spirochete of the genus *Leptospira* (Evangelista & Coburn, 2010). It is a relatively neglected disease, and transmission is more favorable in tropical and urban slum

## OPEN ACCESS

### Jurnal Keperawatan Padjadjaran (JKP)

Volume 11(1), 71-76  
© The Author(s) 2023  
<http://dx.doi.org/10.24198/jkp.v11i1.2176>

#### Article Info

Received : December 01, 2022  
Revised : January 17, 2023  
Accepted : January 30, 2023  
Published : April 27, 2023

#### Corresponding author

**Coana Sukmagautama\***  
Internal Medicine Department, Faculty of Medicine, Sebelas Maret University, Surakarta, Indonesia 57126, Jalan Ir. Sutami 36 Kentingan, Jebres, Surakarta, Jawa Tengah, Indonesia 57126, Phone: (+62) 812-8824-0912, E-mail: [coana.sg@staff.uns.ac.id](mailto:coana.sg@staff.uns.ac.id)

#### Citation

Sukmagautama, C., Muhammad, F., Maharestri, K.Z., Hanif, I., & Myrtha, R. (2023). ST-elevation myocardial infarction, severe cardiogenic shock, and myocarditis secondary to leptospirosis: A rare case report. *Jurnal Keperawatan Padjadjaran*, 11(1), 71-76. <http://dx.doi.org/10.24198/jkp.v11i1.2176>

#### Website

<http://jkp.fkep.unpad.ac.id/index.php/jkp>

This is an **Open Access** article distributed under the terms of the [Creative Commons Attribution-NonCommercial 4.0 International License](https://creativecommons.org/licenses/by-sa/4.0/).

E-ISSN: 2442-7276  
P-ISSN: 2338-5324

Sukmagautama, C., et al. (2023)

environments (Monteiro et al., 2021). The brown rat, *Rattus norvegicus*, is the primary source of human infections, while several wild and domestic animals can become reservoir hosts (Haake & Levett, 2015). A study showed that a considerable degree of morbidity (48%, 95% CI 0.40–0.61) and mortality rate (42%, 95% CI 0.34–0.53) occurs in males aged 20–49 worldwide (Costa et al., 2015). The penetration route of this pathogen includes the skin through abrasion or cut and the conjunctival or oral mucous membranes (De Brito et al., 2018). Its incubation period ranges from 7–12 days, although it can be three days or a month (Haake & Levett, 2015). Later, the hematogenous dissemination causes widespread symptoms ranging from a mild febrile illness to severe multiple organ failure, known as Weil's disease, and death (Rajapakse, 2022).

Severe leptospirosis is known to cause atypical organ dysfunction of cardiac involvement (Mathew et al., 2020). However, the extent of cardiac diseases following leptospirosis is uncertain and underreported (Navinan & Rajapakse, 2012). Thus, we report a rare case of non-severe leptospirosis with cardiac involvement, including ST-elevation myocardial infarction (STEMI), severe cardiogenic shock, and myocarditis at UNS Hospital, Surakarta city, Indonesia.

## Case Presentation

A 35-year-old male patient was admitted to the emergency department on June 21, 2022, with fever for three days, myalgia in his calves, nausea, vomiting, and diarrhea. He worked as a handyman and lived close to the rice fields. There was no recent contact with wild or domesticated animals. No history of hypertension, diabetes and allergies were found. He had quit smoking for more than ten years. Further evaluation revealed low addiction for the Heaviness of Smoking Index (HSI).

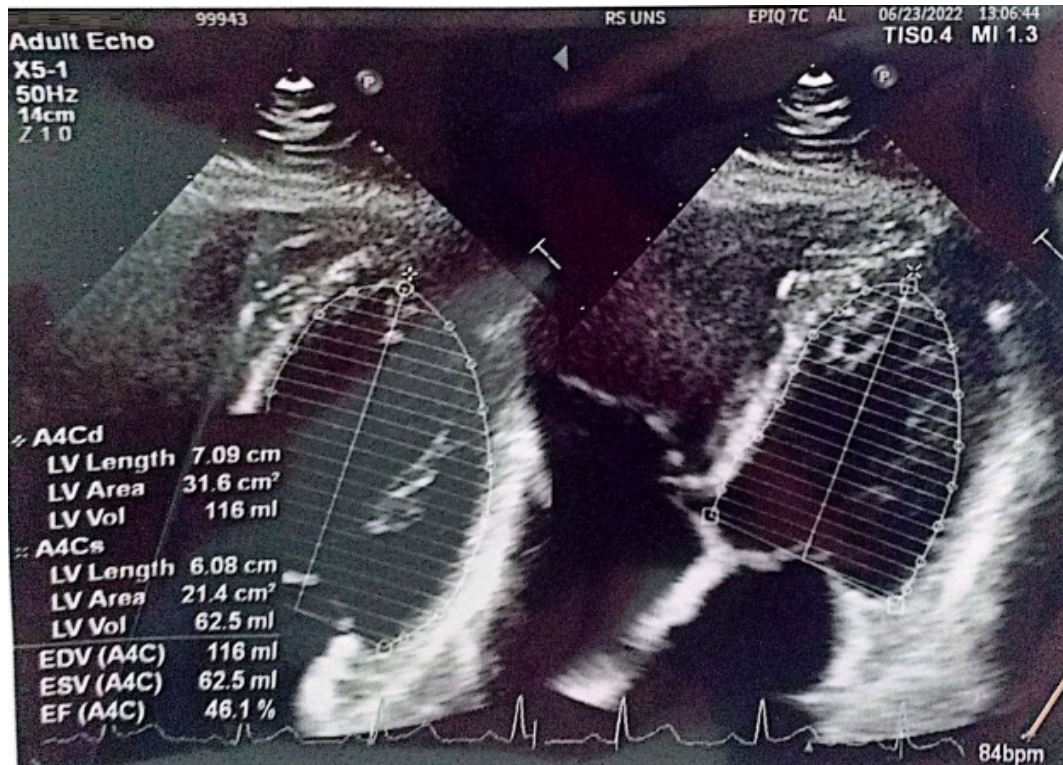
On physical examination, his temperature was 37.9°C with epigastric pain. There were no icterus and signs of bleeding. Laboratory tests (Table 1) showed lymphopenia, neutrophilia, decreased renal function, and negative HbsAg and SARS-CoV-2. Stool examination showed epithelial cells and leukocytes. The patient was initially diagnosed with a common cold, acute gastroenteritis, and acute kidney injury without any specific laboratory findings.

After 24 hours of hospitalization, the patient complained of retrosternal chest pain. Electrocardiogram (ECG) showed ST segment elevation in V1–V6 leads. Elevated high-sensitivity cardiac troponin (hs-cTn) was also detected. Hence, the patient was diagnosed with anterolateral ST elevation myocardial infarction (STEMI). This STEMI

**Table 1. Important Laboratory Profiles of The Patient**

Dates	Laboratory Findings	Interpretation
June 21, 2022	Lymphocytes 5.3% (N: 22.0–44.0), Neutrophil 91.3% (N: 50.0–70.0), Ureum 65 mg/dl (N: 10–45), Creatinine 1.69 mg/dl (N: 0.50–1.10), SGOT 16U/L (N: 8–37), SGPT 13U/L (N: 8–40), HbsAg non reactive; Stool examination: epithelial cells 0–3 (N: 0), WBC 1–2 (N:0), cyst (-), bacteria (-), eggworms (-)	Lymphopenia, neutrophilia, and decreased renal function were found; Diarrhea due to bacteria and parasite infection were excluded.
June 22, 2022	hs-cTn 27542 ng/l (N: 0–2)	Elevated hs-cTn support the diagnosis of myocardial infarction.
June 23, 2022	Haemoglobin 11.5 g/dl (N:13.5–17.5), RBC 4.17x10 <sup>6</sup> /μl (N: 4.50–5.90x10 <sup>6</sup> /micL) MCV 79.9/UM (N: 80.0–96.0), MCH 27.6 pg (N: 28.0–33.0), Thrombocytes 71x10 <sup>3</sup> /μl (N: 150–450x10 <sup>3</sup> /micL), TC 95 mg/dl (N: 0–200), HDL cholesterol 9 mg/dl (N: 30–71), LDL cholesterol 41 mg/dl (N: < 100), TG 147 mg/dl (N:<150)	Microcytic hypochromic anemia and thrombocytopenia were found; Dengue fever was considered as the initial diagnosis; Low HDL level was the only abnormality found in lipid profile examination as a risk factor for ACS.
June 24, 2022	anti-leptospira IgM (+)	Diagnosis of leptospirosis was established.
June 29, 2022	anti-dengue IgM and IgG (-)	Diagnosis of Dengue fever was excluded.

N, normal range; SGOT, Serum Glutamic Oxaloacetic Transaminase; SGPT, serum glutamic-pyruvic transaminase; HbsAg, Hepatitis B surface antigen; hs-cTn, high-sensitivity cardiac troponin; STEMI, ST Elevation Myocardial Infarction; ACS, acute coronary syndrome; HDL, high-density lipoprotein; LDL, low-density lipoprotein; IgM, Immunoglobulin M; IgG, Immunoglobulin G; RBC, red blood cell; TC, total cholesterol; TG, triglyceride.



**Figure 1. Echocardiography illustrated mild mitral and tricuspid regurgitation, mild regional wall motion abnormalities, grade-3 left ventricle (LV) diastolic dysfunction, and amplified echogenicity of the lateral LV endocardium. Based on the Simpson method, the left ventricular systolic function was mildly reduced, with a 46.1% LV ejection fraction.**

circumstance is relatively uncommon in young adult patients with low-grade HSI and without a history of hypertension and diabetes. The lipid profile only showed low-level of high-density lipoprotein (HDL) with normal total cholesterol (TC) and low-density lipoprotein (LDL) levels (Table 1). Acute coronary syndrome (ACS) protocol was performed with the administration of sublingual Isosorbide dinitrate (ISDN) 5 mg, Aspirin loading dose 320 mg, and Clopidogrel 300 mg (de Alencar Neto, 2018).

Within the onset of anterolateral STEMI, the patient experienced a severe cardiogenic shock. The blood pressure was 55/40 mmHg, heart rate 93x/minute, respiratory rate 24x/minute, SpO<sub>2</sub> 91% on nasal cannula 5 lpm, and improved up to 99% on non-rebreathing mask 10 lpm. Acral coldness and prolonged capillary refill time were found. The patient was then transferred into the High Care Unit (HCU).

The treatment in HCU included adequate oxygenation, norepinephrine 0.01 mcg/kg bodyweight/minute, and 5 mg dexamethasone intravenous (IV). The patient did not have any absolute contraindication of fibrinolytic. Streptokinase 1.5 million units and heparin 60 IU/kg bodyweight were administered since percutaneous coronary intervention (PCI) is unavailable in our hospital. Heparin continued at 12 IU until the fifth day (Ibanez et al., 2018).

On the second day, a routine complete blood

count test showed hypochromic microcytic anemia, leukocytosis with lymphopenia, neutrophilia, and thrombocytopenia. We suspected leptospirosis and dengue hemorrhagic fever (DHF). Further tests showed positive anti-leptospira IgM and negative anti-dengue IgM and IgG (Table 1). Echocardiography was conducted due to the presence of fine crackles and revealed myocarditis (Figure 1).

## Results

We diagnosed leptospirosis, myocarditis, and STEMI with severe cardiogenic shock. Leptospirosis and cardiac involvement is a rare coincidence as leptospiral vasculitis usually does not involve cardiac tissue. Further evaluation showed no evidence of Weil's disease due to the absence of refractory shock, pulmonary hemorrhage, and jaundice (Satiya et al., 2020). Pharmacology therapies included Aspirin 80 mg o.d., Atorvastatin 40 mg o.d., Clopidogrel 75 mg o.d., Spironolactone 50 mg o.d., Ramipril 2.5 mg b.i.d., Carvedilol 6.25 mg b.i.d., Omeprazole 40mg IV o.d., Doxycycline 100 mg b.i.d., and Ceftriaxone 2 g IV o.d.

The patient was discharged from HCU to the hospital ward on the sixth day of hospitalization. He continued to receive Omeprazole 40 mg IV o.d., Doxycycline 100 mg b.i.d., Ceftriaxone 2 g IV o.d. On the ninth day, he was discharged from the

Sukmagautama, C., et al. (2023)

hospital. Home remedies included cardiovascular medications, antibiotics, antiplatelet, potassium-sparing diuretics, and omeprazole. One week later, the patient was doing well. No recurrence of symptoms was reported during hospital follow-up.

## Discussion

Leptospirosis is a fatal zoonosis and can cause significant epidemics following periods of heavy rainfall and flooding (Monteiro et al., 2021). We suspected that the patient was infected by leptospiral-contaminated wet soil. Our patient presented with a nonspecific-acute febrile, nausea, vomiting, and diarrhea with severe myalgia in both his calves. Those symptoms may be diagnosed as influenza, DHF, dengue fever, typhoid fever, other enteric fever, and hepatitis A (Warnasekara et al., 2022). Typhoid fever was excluded because of the absence of step-ladder pattern fever (Britto et al., 2017). Hepatitis A was not considered because we found no jaundice and no history of food or water ingestion that had been contaminated with the stool of an infected and jaundice person (Becirovic et al., 2020).

Thrombocytopenia can be found in either early DHF or late complications of severe leptospirosis (Costa et al., 2015). However, we did not consider DHF diagnostic because of negative results of anti-dengue IgM and IgG. The microscopic agglutination test (MAT) is the gold standard for diagnosing most leptospirosis-suspected patients (Haake & Levett, 2015). However, due to the lack of accessibility to MAT in our hospital, this case diagnosis was established by IgM-anti leptospiral antibody detection. Several studies showed that IgM-anti leptospiral had average specificity and sensitivity of 84.5-73.3% and 86.0-87.4%, respectively (Costa et al., 2015).

The cardiac involvement pathomechanism in leptospirosis is poorly studied (Misra & Shenoy, 2017). In mild-moderate leptospirosis, systemic vasculitis is exacerbated by direct tissue damage by leptospiral, disseminated intravascular coagulation, and cytokine storm with higher titers of IL-6, IL-10, and TNF- $\alpha$  are assumed to result in coronary endothelial dysfunction and heart muscle damage (Navinan & Rajapakse, 2012). A study found that interstitial myocarditis, an abnormal histopathological change with cellular infiltrate, accounted for 96% of postmortem studies of severe leptospirosis (Costa et al., 2015).

Given the lack of advance-definitive diagnostic approaches such as echocardiography and myocardial biopsy, a cardiologist's working group has developed clinical and diagnostic criteria for myocarditis in leptospirosis and other vasculitis-based diseases (Costa et al., 2015). These criteria include unexplained severe cardiogenic shock, positive hs-cTn, and non-specific variable ECG changes. These ECG changes can be bundle branch

blocks, STEMI, atrial fibrillation, first-and-third-degree heart block, ventricular and supraventricular extrasystoles, changes in the P-QRS-T complexes, low voltage QRS complexes, and ST-T wave disturbances (Costa et al., 2015).

Our patient received oral doxycycline due to the absence of Weil's disease signs and symptoms. Mild leptospirosis therapy options include oral Doxycycline and Amoxicillin. Meanwhile, high-dose intravenous Penicillin G still becomes the drug of choice in severe cases (Rajapakse, 2022). The third-generation Cephalosporin such as Cefotaxime and Ceftriaxone have shown promising outcomes in recent clinical trials (Rajapakse, 2022). However, no specific and evidence-based therapies are available for cardiac leptospirosis; current treatments are supportive therapy and correction of hemodynamic derangement in the intensive or high care unit (Navinan & Rajapakse, 2012). In our case, anterolateral STEMI was treated according to ACS guidelines. An inotropic agent was administered to preserve hemodynamic stability during cardiogenic shock (Shah et al., 2019).

Cardiac involvement is usually found in severe leptospirosis patients and is related to a 43% mortality rate (Navinan & Rajapakse, 2012). Myocarditis, pericarditis, arrhythmias, cardiogenic shock, massive bleeding of the myocardium, STEMI, and congestive heart failure are associated with acute stages of cardiac morbidity and mortality in leptospirosis patients (Rajapakse, 2022). Different innate immune response may cause cardiac involvement, in our mild case leptospirosis. It plays a crucial role in early recognition and elimination of the bacteria. The immune reaction will result in pathogen recognition receptors (PRRs) recognizing pathogen-associated molecular patterns. Those two dominant PRRs are Toll-like receptors (TLRs) and the Nod-like receptors (NLRs). In leptospirosis, TLR2 and LTR4 are the most identified PRRs (Fraga et al., 2011). They cause chemokine dependent response and pro-inflammatory cytokine; however, despite leptospiral the carbohydrate moiety of leptospiral lipopolysaccharide (LPS) is less endotoxic (Chen et al., 2020). This lower LPS endotoxicity profile explained the mild leptospiral in our rare case.

This study has some limitations. The MAT is unavailable in our hospital. Hence, we recommend our hospital and all secondary-to-tertiary referral hospitals to provide a MAT diagnostic facility (Gasem et al., 2020). This case was relatively mild-to-moderate leptospirosis, yet the patient suffered severe cardiac involvement of STEMI and severe cardiogenic shock. Meanwhile, several studies of cardiac involvement have been reported in severe leptospirosis. Clinical outcomes of leptospirosis with cardiac involvement in our country are also unclear since there is a lack of reported cases despite high leptospirosis incidence in the rainy season and flood-prone areas.

## Conclusions

The cardiac involvement of STEMI, cardiogenic shock, and myocarditis in a leptospiral-suspected patient can cause medical overdiagnosis, although those are secondary to leptospirosis. This atypical organ dysfunction is difficult to describe because of the lack of clear criteria to define cardiac involvement. The possible co-infection of enteric and dengue fever in leptospirosis should also be evaluated in the physical-laboratory examination and treatment, especially in tropical-endemic countries. Supportive, hemodynamic derangement, and antibiotic therapies should be addressed in leptospirosis with cardiac involvement.

## Acknowledgements

The authors are grateful to internal medicine colleagues in UNS Hospital for providing feedback and manuscript proofreading.

## Funding

None.

## Ethics statement

Written informed consent was obtained from the patient. This study is approved by Health and Research Committee of Dr. Moewardi Hospital (No.013/I/HREC/2023).

## Data Availability

Please contact on reasonable request: [coana.sg@staff.uns.ac.id](mailto:coana.sg@staff.uns.ac.id).

## Conflict of Interests

The authors have no conflict of interests.

## References

- de Alencar Neto, J. N. (2018). Morphine, oxygen, nitrates, and mortality reducing pharmacological treatment for acute coronary syndrome: An evidence-based review. *Cureus*, *10*(1), e2114. <https://doi.org/10.7759/cureus.2114>
- Becirovic, A., Numanovic, F., Dzafic, F., & Piljic, D. (2020). Analysis of clinical and laboratory characteristics of patients with leptospirosis in five-year period. *Materia Socio Medica*, *32*(1), 15. <https://doi.org/10.5455/msm.2020.32.15-19>
- Britto, C., Pollard, A. J., Voysey, M., & Blohmke, C. J. (2017). An appraisal of the clinical features of pediatric enteric fever: Systematic review and meta-analysis of the age-stratified disease occurrence. *Clinical Infectious Diseases*, *64*(11), 1604–1611. <https://doi.org/10.1093/cid/cix229>
- Chen, X., Xie, X., Wu, D., Zhang, S., Zhang, W., & Cao, Y. (2020). The pre-activated immune response induced by LPS protects host from leptospirosis. *Plos One*, *15*(11), e0242742. <https://doi.org/10.1371/journal.pone.0242742>
- Costa, F., Hagan, J. E., Calcagno, J., Kane, M., Torgerson, P., Martinez-Silveira, M. S., Stein, C., Abela-Ridder, B., & Ko, A. I. (2015). Global morbidity and mortality of leptospirosis: A systematic review. *PLoS Neglected Tropical Diseases*, *9*(9). <https://doi.org/10.1371/JOURNAL.PNTD.0003898>
- De Brito, T., Silva, A. M. G. da, & Abreu, P. A. E. (2018). Pathology and pathogenesis of human leptospirosis: A commented review. *Revista Do Instituto de Medicina Tropical de São Paulo*, *60*, e23. <https://doi.org/10.1590/s1678-9946201860023>
- Evangelista, K. V., & Coburn, J. (2010). Leptospira as an emerging pathogen: A review of its biology, pathogenesis and host immune responses. *Future Microbiology*, *5*(9), 1413–1425. <https://doi.org/10.2217/fmb.10.102>
- Fraga, T. R., Barbosa, A. S., & Isaac, L. (2011). Leptospirosis: Aspects of innate immunity, immunopathogenesis and immune evasion from the complement system. *Scandinavian Journal of Immunology*, *73*(5), 408–419. <https://doi.org/10.1111/j.1365-3083.2010.02505.x>
- Gasem, M. H., Hadi, U., Alisjahbana, B., Tjitra, E., Hapsari, M. M. D. E. A. H., Lestari, E. S., Aman, A. T., Lokida, D., Salim, G., Kosasih, H., Merati, K. T. P., Laras, K., Arif, M., Lukman, N., Sudarmono, P., Lisdawati, V., Lau, C.-Y., Neal, A., & Karyana, M. (2020). Leptospirosis in Indonesia: Diagnostic challenges associated with atypical clinical manifestations and limited laboratory capacity. *BMC Infectious Diseases*, *20*(1), 179. <https://doi.org/10.1186/s12879-020-4903-5>
- Guzmán Pérez, M., Blanch Sancho, J. J., Segura Luque, J. C., Mateos Rodriguez, F., Martínez Alfaro, E., & Solís García del Pozo, J. (2021). Current evidence on the antimicrobial treatment and chemoprophylaxis of human leptospirosis: A meta-analysis. *Pathogens*, *10*(9), 1125. <https://doi.org/10.3390/pathogens10091125>
- Haake, D. A., & Levett, P. N. (2015). Leptospirosis in humans. *Current Topics in Microbiology and Immunology*, *387*, 65. [https://doi.org/10.1007/978-3-662-45059-8\\_5](https://doi.org/10.1007/978-3-662-45059-8_5)
- Ibanez, B., James, S., Agewall, S., Antunes, M. J., Bucciarelli-Ducci, C., Bueno, H., Caforio, A. L. P., Crea, F., Goudevenos, J. A., Halvorsen, S., Hindricks, G., Kastrati, A., Lenzen, M. J., Prescott, E., Roffi, M., Valgimigli, M., Varenhorst, C., Vranckx, P., Widimský, P., ... Gale, C. P. (2018). 2017 ESC Guidelines for the management of acute myocardial infarction in patients presenting with ST-segment elevation. *European Heart Journal*, *39*(2), 119–177. <https://doi.org/10.1093/eurheartj/ehx393>
- Mathew, A., Shanks, M., Punnoose, E., Fischer, L., Koshy, G., Potturi, R., & Bainey, K. R. (2020). Cardiac involvement in critically ill patients with leptospirosis: A prospective

Sukmagautama, C., et al. (2023)

- study using myocardial deformation imaging. *European Heart Journal. Acute Cardiovascular Care*, 9(8), 975–983. <https://doi.org/10.1177/2048872618809319>
- Misra, D. P., & Shenoy, S. N. (2017). Cardiac involvement in primary systemic vasculitis and potential drug therapies to reduce cardiovascular risk. *Rheumatology International*, 37(1), 151–167. <https://doi.org/10.1007/s00296-016-3435-1>
- Monteiro, M. B., Sousa, I. E. de, Piteira, M., Coelho, S., & Freitas, P. (2021). Leptospirosis, a re-emerging threat. *Cureus*, 13(4). <https://doi.org/10.7759/CUREUS.14295>
- Navinan, M. R., & Rajapakse, S. (2012). Cardiac involvement in leptospirosis. *Transactions of the Royal Society of Tropical Medicine and Hygiene*, 106(9), 515–520. <https://doi.org/10.1016/J.TRSTMH.2012.06.007>
- Rajapakse, S. (2022). Leptospirosis: Clinical aspects. *Clinical Medicine*, 22(1), 14. <https://doi.org/10.7861/CLINMED.2021-0784>
- Satiya, J., Gupta, N. M., & Parikh, M. P. (2020). Weil's disease: A rare cause of jaundice. *Cureus*, 12(6), e8428. <https://doi.org/10.7759/cureus.8428>
- Shah, A. H., Puri, R., & Kalra, A. (2019). Management of cardiogenic shock complicating acute myocardial infarction: A review. *Clinical Cardiology*, 42(4), 484–493. <https://doi.org/10.1002/clc.23168>
- Warnasekara, J., Srimantha, S., Kappagoda, C., Jayasundara, D., Senevirathna, I., Matthias, M., Agampodi, S., & Vinetz, J. M. (2022). Diagnostic method-based underestimation of leptospirosis in clinical and research settings; An experience from a large prospective study in a high endemic setting. *PLOS Neglected Tropical Diseases*, 16(4), e0010331. <https://doi.org/10.1371/journal.pntd.0010331>